

Familial Adenomatous Polyposis In Association With Colonic Carcinoma- A Case Report



Medical Science

KEYWORDS : Familial adenomatous polyposis, colorectal cancer, Autosomal dominant

Dr Vikas kumar	PG Resident, Pathology, Mahatma Gandhi Medical College,
Dr Utsav Joshi	PG Resident, Pathology, Mahatma Gandhi Medical College
Dr Narayani Joshi	Professor and Head, Pathology, Mahatma Gandhi Medical College
Dr B . P. Nag	Professor, Pathology, Mahatma Gandhi Medical College
Dr R. M Jaiswal	Associate Professor, Pathology, Mahatma Gandhi Medical College

ABSTRACT

Introduction: Familial adenomatous polyposis (FAP) is an autosomal dominant disorder in which patient develops numerous colorectal adenomas as teenagers. It is caused by mutations of the adenomatous polyposis coli or APC gene. At least 100 polyps are necessary for a diagnosis of classic FAP and as many as several thousand may be present. Colorectal adenocarcinoma develops in 100% of untreated FAP patients before age 30.

Material and methods: A 36 year old male presented with swelling in abdomen, increased frequency of stools & a positive family history of similar complaints. Sigmoidoscopy of sigmoid colon reveals multiple sessile polyps of varying size along with a large proliferative friable growth. Superficial biopsy was taken & subjected to histopathology examination. And later a full colectomy was done.

Results: Superficial biopsy shows features consistent with an intramucosal carcinoma. Later, Colectomy specimen was received. On gross examination, colon is studded with numerous sessile polyps measuring 0.5 to 0.7 cm in diameter. An ulcerated area is also seen. On microscopic examination features were in favour of moderately differentiated adenocarcinoma.

Discussion: Familial adenomatous polyposis is an inherited disorder characterized by cancer of large intestine and rectum and accounts for 1 percent of all cases of colorectal cancer. Most individuals with APC mutation will develop colon cancer by the age of 30. Therefore prophylactic surgery is generally recommended before the age of 25. Making the diagnosis of FAP before the development of colon cancer is important not just for individual, but also for the sake of other family members who may be affected.

Introduction

Familial Adenomatous Polyposis (FAP) is an autosomal dominant disorder in which Patients develop numerous colorectal adenomas in teenage. It is caused by mutations of the Adenomatous Polyposis Colior APC gene¹

At least 100 polyps are necessary for the diagnosis of classic FAP and as many as several thousand may be present. Except for their remarkable numbers, these growths are morphologically indistinguishable from sporadic adenomas.

Colorectal adenocarcinoma develops in 100% of untreated FAP patients, often before the age of 30².

FAP is associated with variety of extra-intestinal manifestations including congenital hypertrophy of the Retinal pigment epithelium, which can generally be detected at birth and can be an adjunct to early screening¹.

CASE REPORT:

We present a case of a 36 year old male, who presented with the complains of abdomen swelling and increased frequency of defecation.

On examination:- General physical examination was unremarkable

Systemic Examination : P/A - soft with tenderness at right iliac fossa and left iliac fossa

Investigations:

1) CECT abdomen and pelvis- Enhancing wall thickening in sigmoid colon & distal descending colon with small loculated peridodic collection and minimal ascitis ; hepatomegaly was present

2) Sigmoidoscopy- Multiple sessile polyps of varying size with a large proliferative friable growth was seen. A sigmoidoscopic biopsy was taken :

Microscopy of biopsy revealed - features consistent with an intramucosal carcinoma

Few glandular structures are seen entrapped in/infiltrating mucosae.

SURGERY:

Total colectomy and ileorectal anastomosis was done. Specimen was sent to the Department of Pathology, Mahatma Gandhi Medical College.

Gross Examination :



Fig-1 Gross specimen of cecum with colonic polyp



Fig-2 Gross specimen showing multiple sessile polyp and growth

Colectomy specimen measuring 70 cm in length with serosal surface gray-white to gray-brown and areas of congestion were seen. Proximal resected end shows appendix measuring 10cms in length and normal intestine rugosities seen upto 6cm from the same end on the mucosal surface. Rest of the colon is studied with numerous sessile polyps measuring 0.7 to 0.5 cm in diameter. At distal resected end 5 cm from the end, wall was thickened and small area was devoid of polyps measuring 2.5cm in diameter. An ulceration was seen corresponding to this area, with gray-brown area was seen externally on serosal surface. 24 lymph nodes are resected ranging in size from 1×1 to 0.5×0.5 cm.

Microscopic Examination:

Sections given from growth shows moderately differentiated adenocarcinoma infiltrating upto muscularis propria. The serosal layer was densely infiltrated by acute and chronic non-specific inflammatory cells with histiocytic giant cell reaction -Duke stage A.Both resected end were free from growth.

Appendix was unremarkable

Numerous polyps seen in the colon shows histopathological features of adenomatous polyps. Many of these polyps revealed mild to moderate dysplasia.

Lymph node resected shows reactive hyperplasia and sinus histiocytosis.

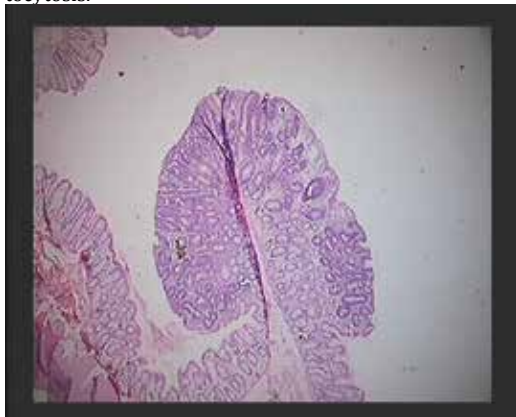

Fig-3 showing adenomatous polyp with mild to moderate dysplasia ; H&E(5X)

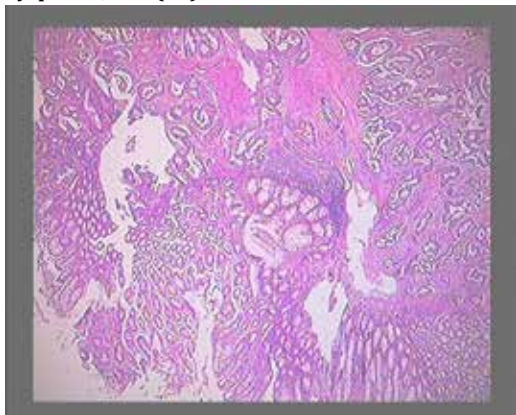


Fig-4Showing normal feature with growth extending upto muscularis propria and chronic non specific inflammatory cell infiltrate ; H&E(5x)

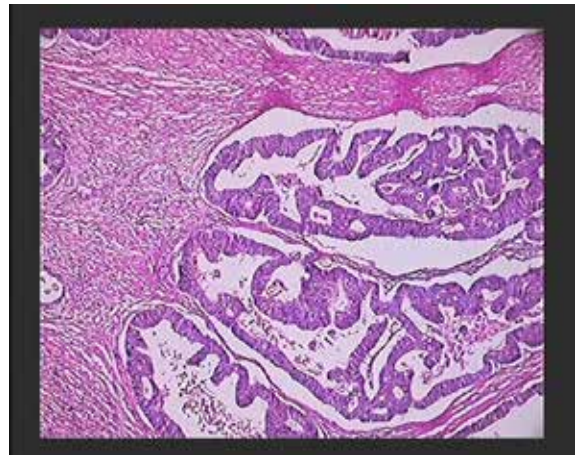


Fig-5 showing features of adenocarcinoma ; H&E(10x)

Results & Conclusion:

Familial Adenomatous Polyposis is an inherited disorder in which numerous adenomatous polyps form mainly in the epithelium of the large intestine. While these polyps start out benign, malignant transformation into colon cancer occurs when left untreated. Carcinoma of large intestine and rectum accounts for 1% of all cases of colorectal carcinoma.

Colorectal adenocarcinoma develops in 100% of untreated FAP patients, often before the age of 30.

Making the diagnosis of FAP before the development of colon cancer is important not just for individual but also for the sake of other family members who may be affected. Therefore, prophylactic surgery is generally recommended before the age of 25.

Discussion:

A polyp is a tissue growth protruding from the mucous membrane into the lumen of GI tract.

Some people have a variant of the disorder, called attenuated FAP, in which polyp growth is delayed. A milder type of, autosomal recessive FAP has also been identified. Screening of family members is helpful in early identification of disease. There is also an increased chance of developing cancer in the stomach and/or small intestines. Other types of cancer found in families with FAP include hepatoblastoma (a type of liver cancer seen in young children); papillary thyroid cancer; pancreatic, adrenal, and bile duct cancers; and a low risk type of brain cancer called medulloblastoma.

REFERENCE

1. Robbins and Cotran Pathological Basis of Disease 8TH Edition, The Gastrointestinal Tract Page no 820-21 | 2. Hes FJ et al.: Somatic APC mosaicism: an underestimated cause of polyposis coli. Gut 57:71,2008 | 3. Galiatsatos P, Foulkes WD: Familial adenomatous polyposis. Am J Gastroenterol 101:385,2006 | 4. Familial Adenomatous Polyps with synchronous colorectal carcinoma, Sushama et al, International Journal of recent trends in science and Technology; ISSN2277-2812 E-ISSN2249-8109, volume 5, issue 3, 2013 pp152-154 | 5. Familial Adenomatous polyposis -Associated Thyroid cancer, Am J Pathol. 1999 January; 154(1):127-135 | 6. Familial Adenomatous Polyposis, oncologist-approved cancer information from the American Society of clinical Oncology, Cancer.Net | 7. AJCC Cancer staging Manual (Sixth ed.). Springer-Verlag New York, inc. 2002. | 8. Astler VB, Collier FA: The prognostic significance of direct extension of carcinoma of the colon and rectum. Ann Surg 139:846,1954 | 9. Atypical presentation of colon adenocarcinoma: A case report, Lynnete k Tumwine et al, Journal of Medical Case Reports 2012, 6:58 |